



Optimized using
trial version
www.balesio.com

Diabetes

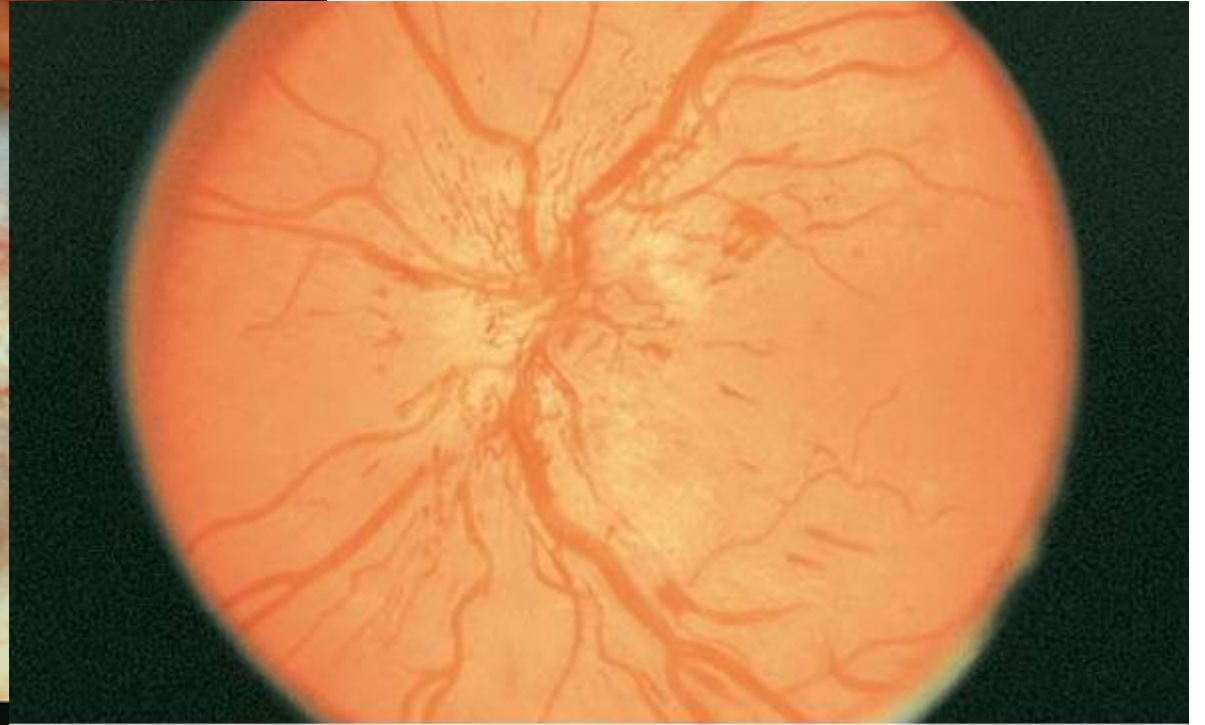
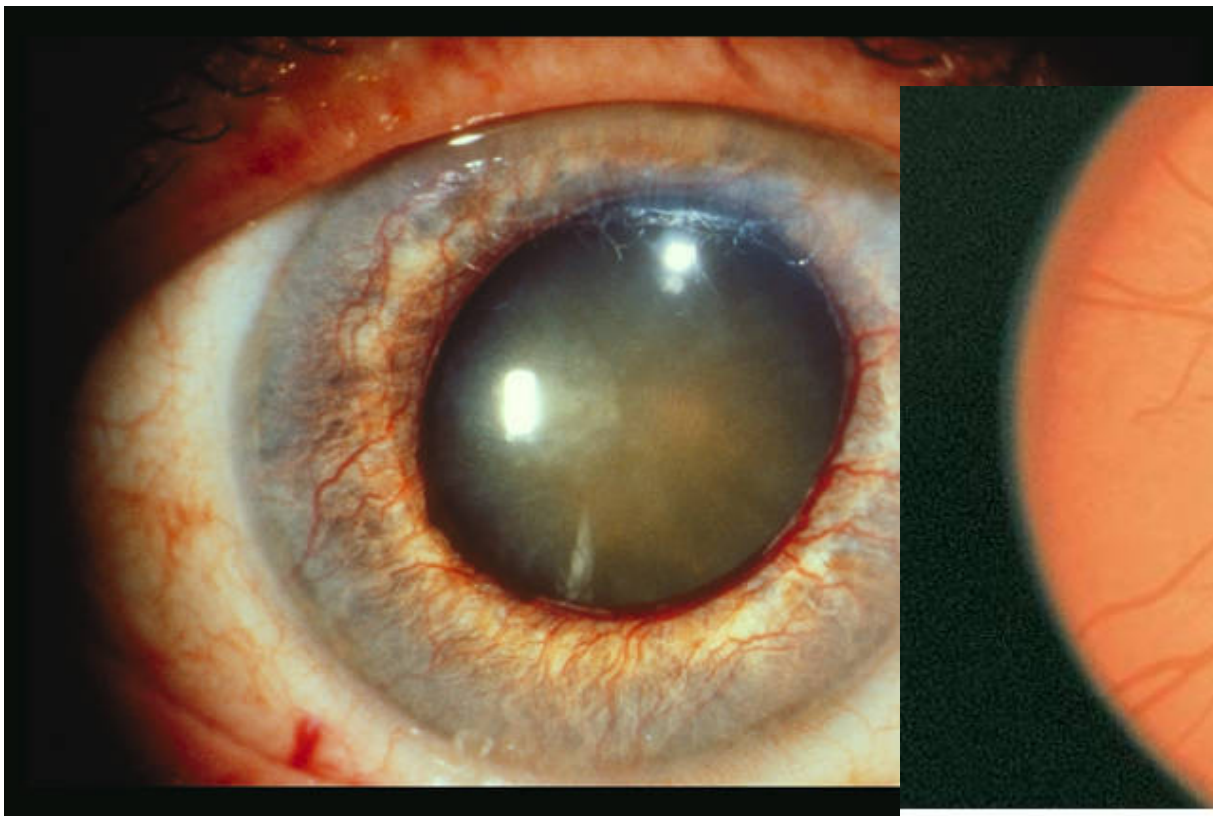
- Blefaritis anterior
- Retarda la cicatrización epitelial
- Parálisis de MOE
- Iris: iridopatía diabética (mala midriasis, defectos de transiluminación)
- Cristalino: 1,6 veces + frecuencia de catarata (nuclear de comienzo precoz, “en copo de nieve”)
- Glaucoma: 1,4 veces + frecuencia de GCAA



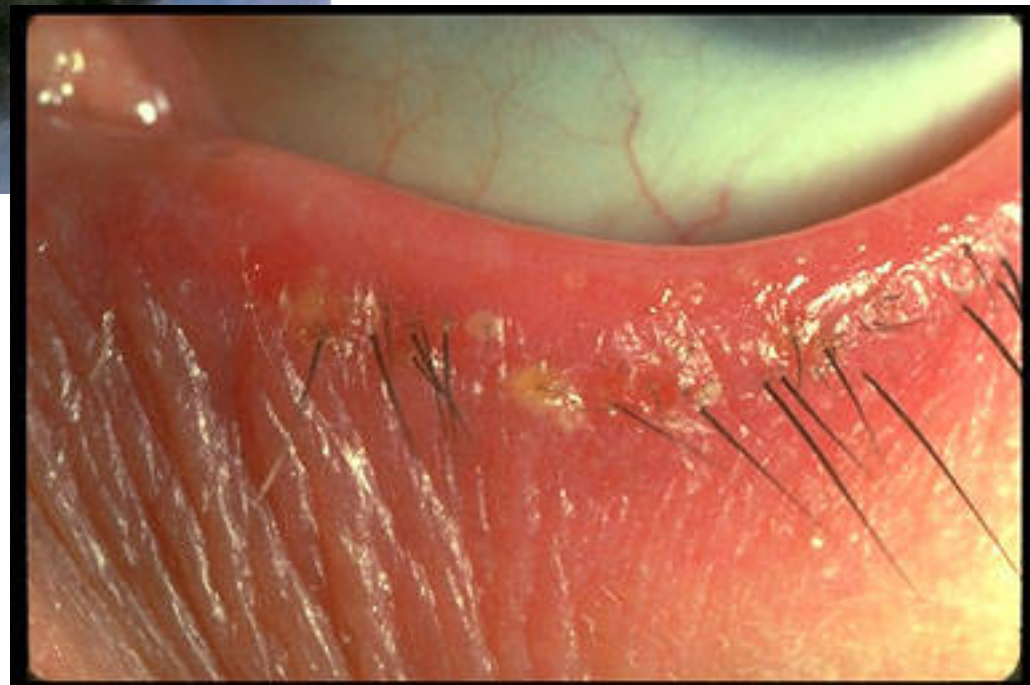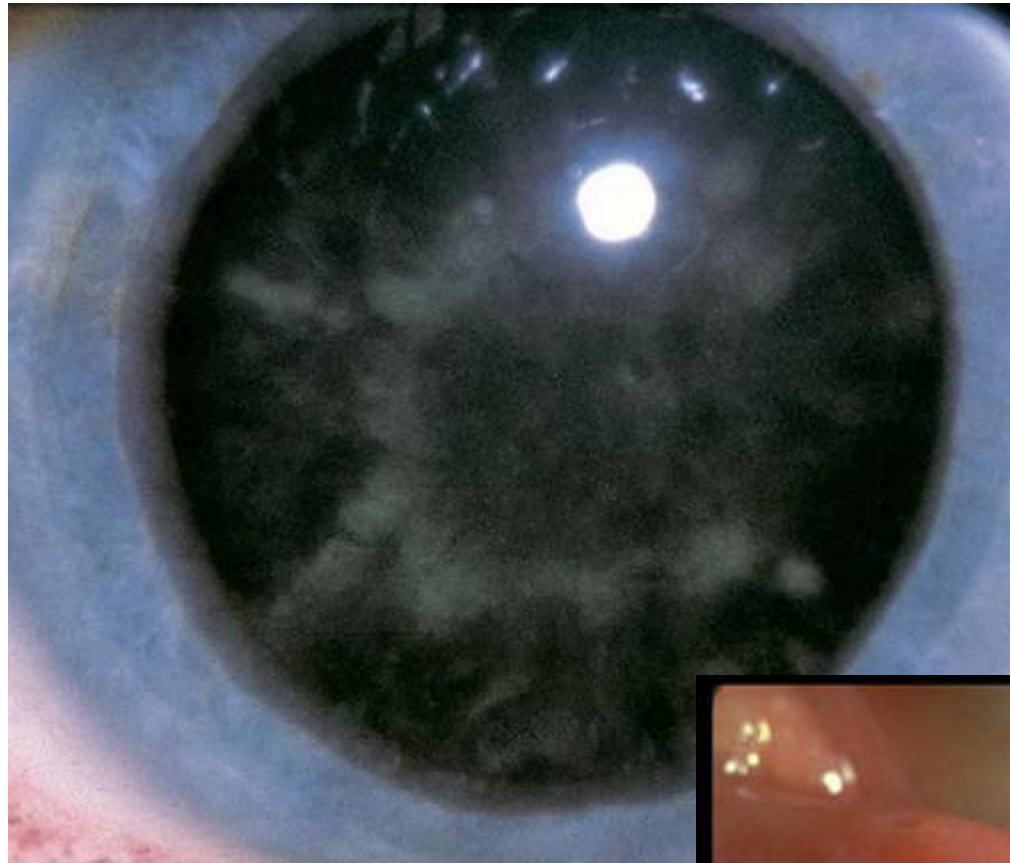
Retinopatía diabética: DPA, EMQ, hemovítreo, neovascularización, atropia, iris...

Diabetes materna se asocia a hipoplasia del nervio óptico

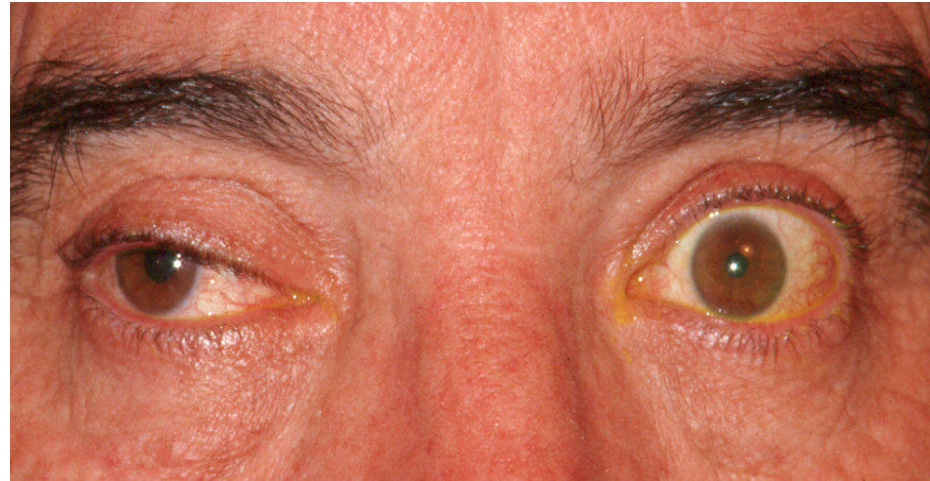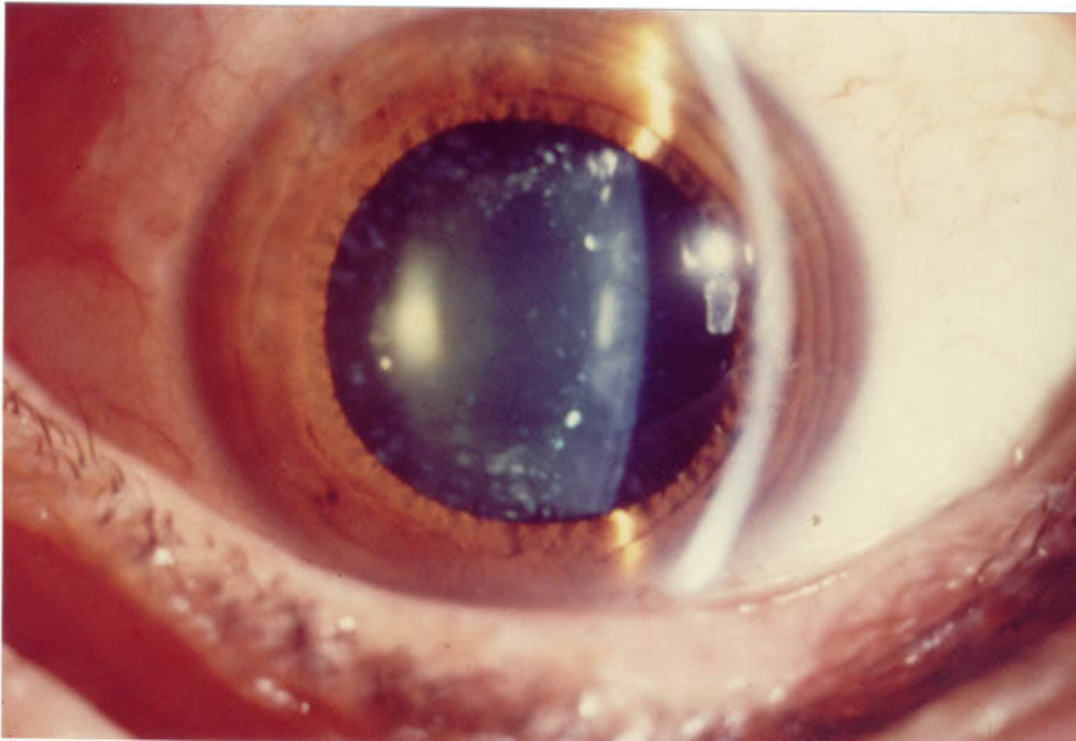
- DIDMAOS, Sd. Poliglandular, ...



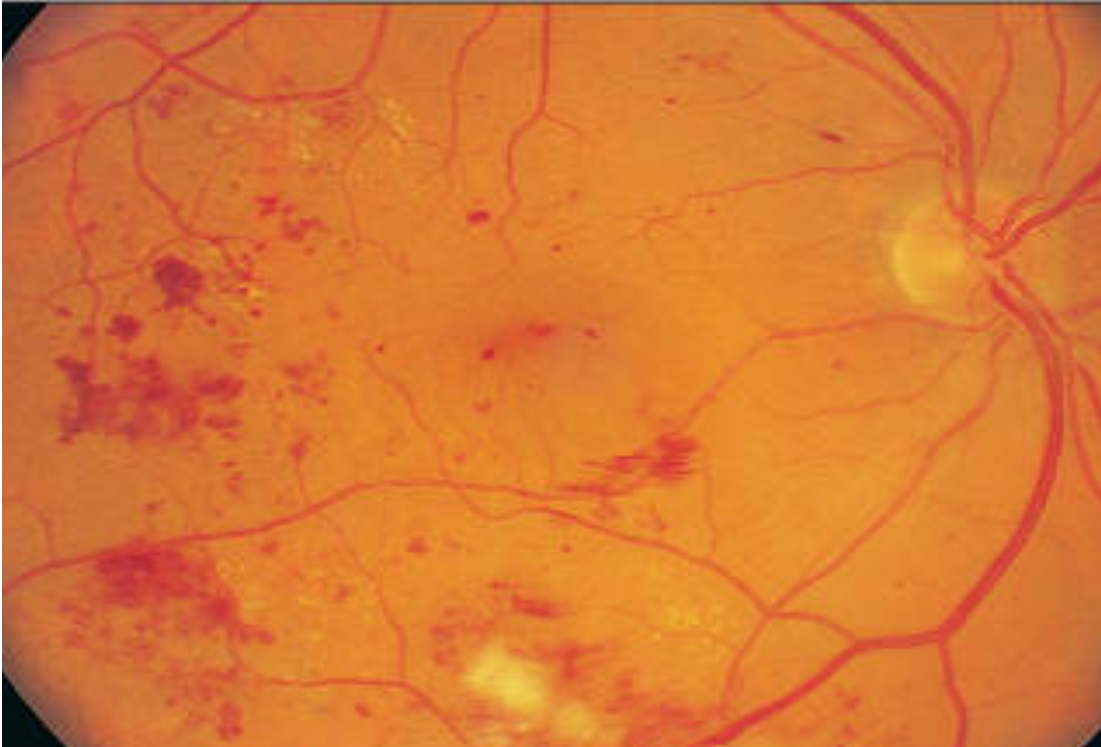
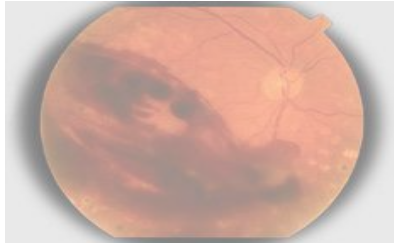
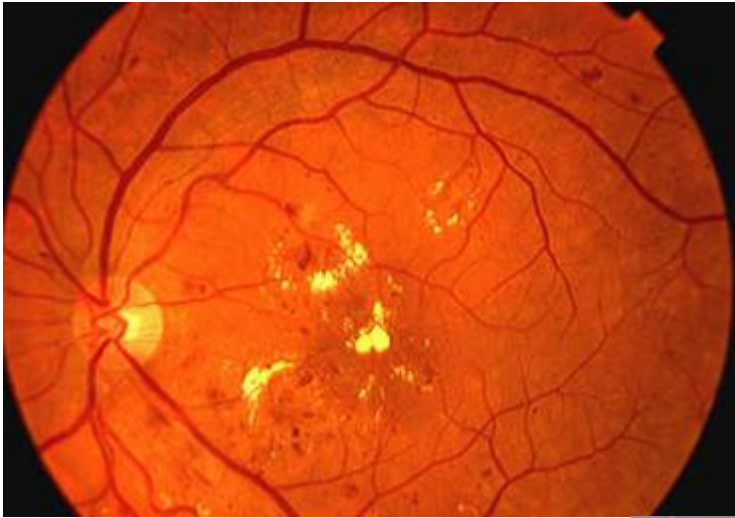
Optimized using
trial version
www.balesio.com



Optimized using
trial version
www.balesio.com



Optimized using
trial version
www.balesio.com



Optimized using
trial version
www.balesio.com