Tuberculosis ocular

Autofluorescencia y tratamiento sistémico

Unidad de Uveítis
Complexo Hospitalario de Pontevedra

Optimized using
trial version
www.balesio.com

Introducción

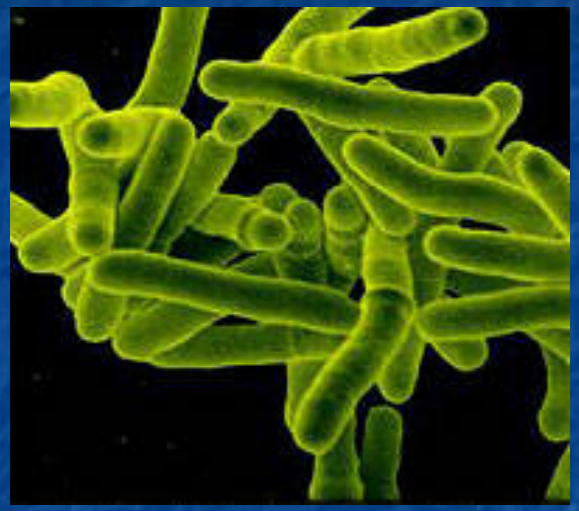

- Micobact. Tuberculosis
- Aumento de incidencia
- Dx
  - Visualización directa/Cultivo de esputos
  - TB latente: Mantoux +,clínica compatible, descarte de otras patologías, respuesta a tto
- to: IREP 10meses, IR 4 meses

Optimized using
trial version
www.balesio.com

TB intraocular

- 1,5 % - 11% según zonas
- Dx difícil
  - Muestras pequeñas
  - Extracción cruenta
  - Carácter inmunológico
- Todas las capas histológicas

esentación + habitual: coroiditis

Optimized using
trial version
www.balesio.com

Etiopatogenia

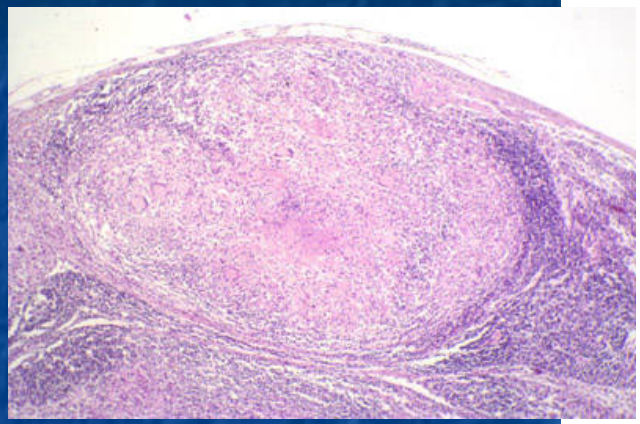

- Hipersensibilidad tipo IV
- Carácter inmunológico
  - Linfocitos T CD4 y 8, CQ, IFNgamma, TNFalfa
  - Macrófagos-Apoptosis-Daño tisular
- Necrosis caseosa
- Vía hematógena
  - Anatomía patológica: entre EPR y retina
  - Haen, Spaide

Optimized using
trial version
www.balesio.com

Clínica

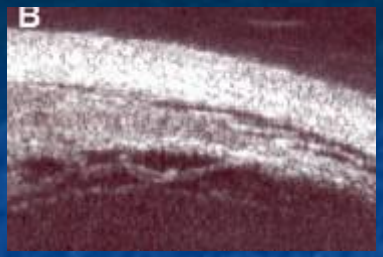

- Uveítis anteriores (34%)
- Uveítis intermedias (16%) (9% panuveítis)
- Escleritis
- Tuberculosis orbitaria
- Uveítis posteriores (41%)
  - Coroiditis
  - Tuberculomas, tubérculos coroideas, abscesos subretinianos

Serpiginosa/Eales

Vasculitis, neurorretinitis, neuropatía óptica

Optimized using
trial version
www.balesio.com

cas

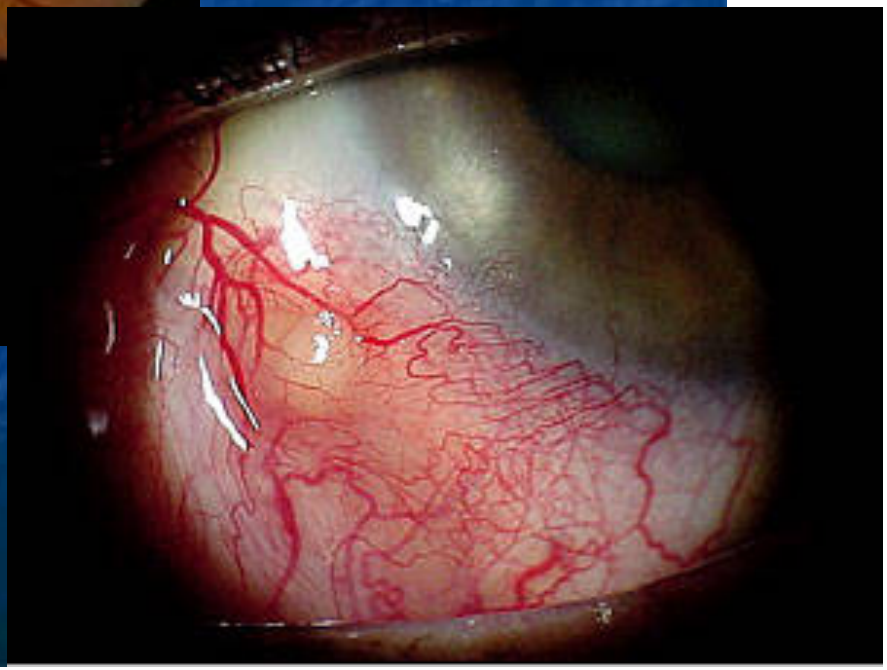

Optimized using
trial version
www.balesio.com

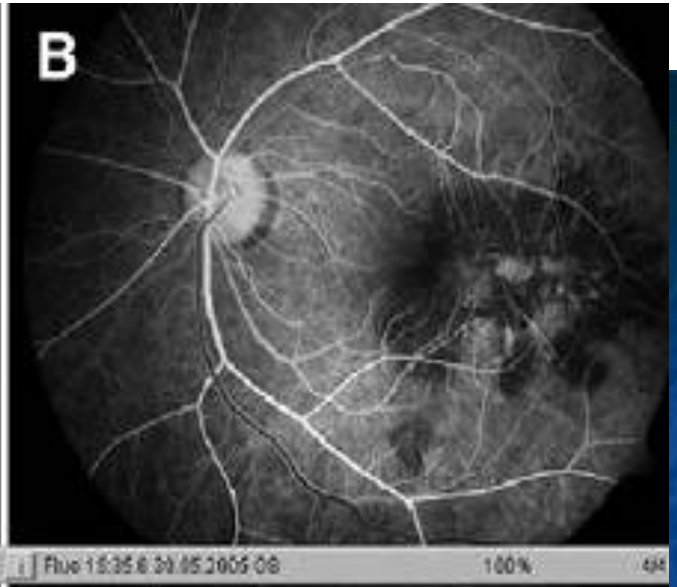

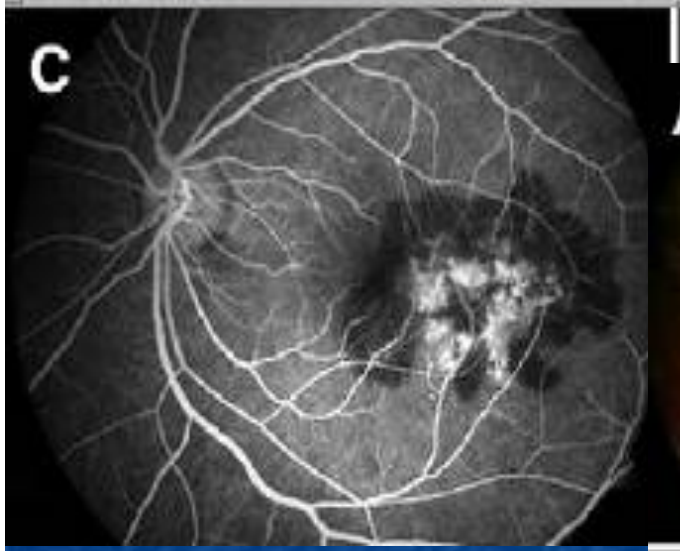

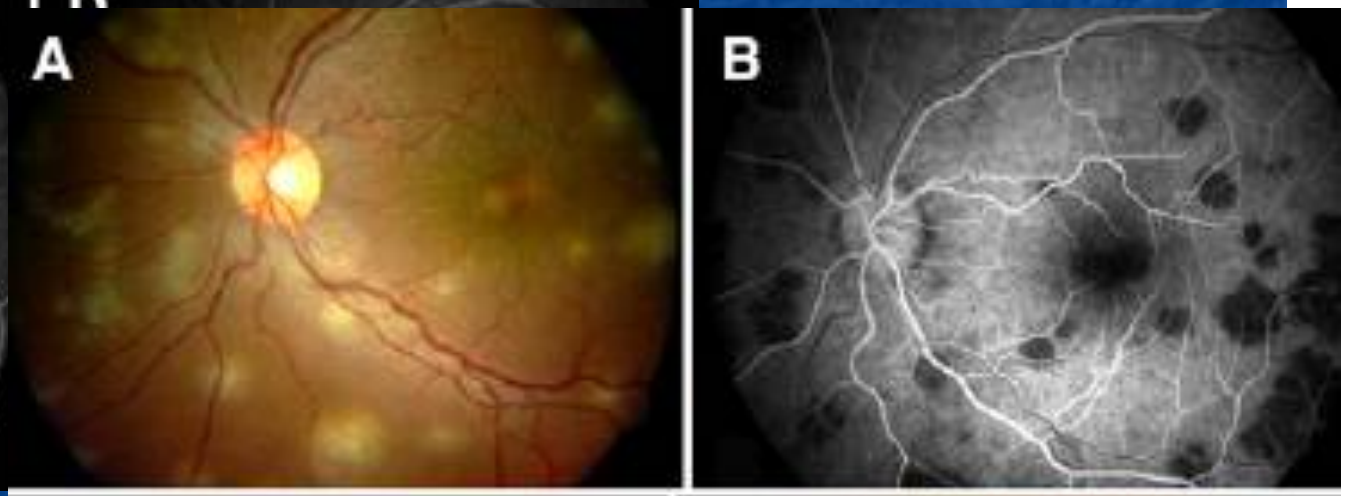

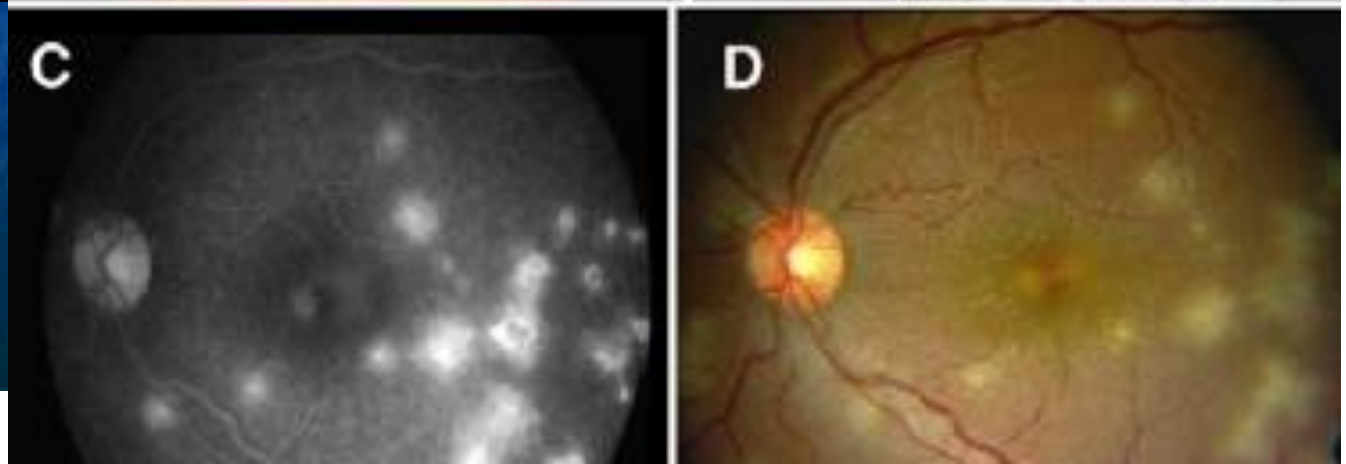

Optimized using
trial version
www.balesio.com

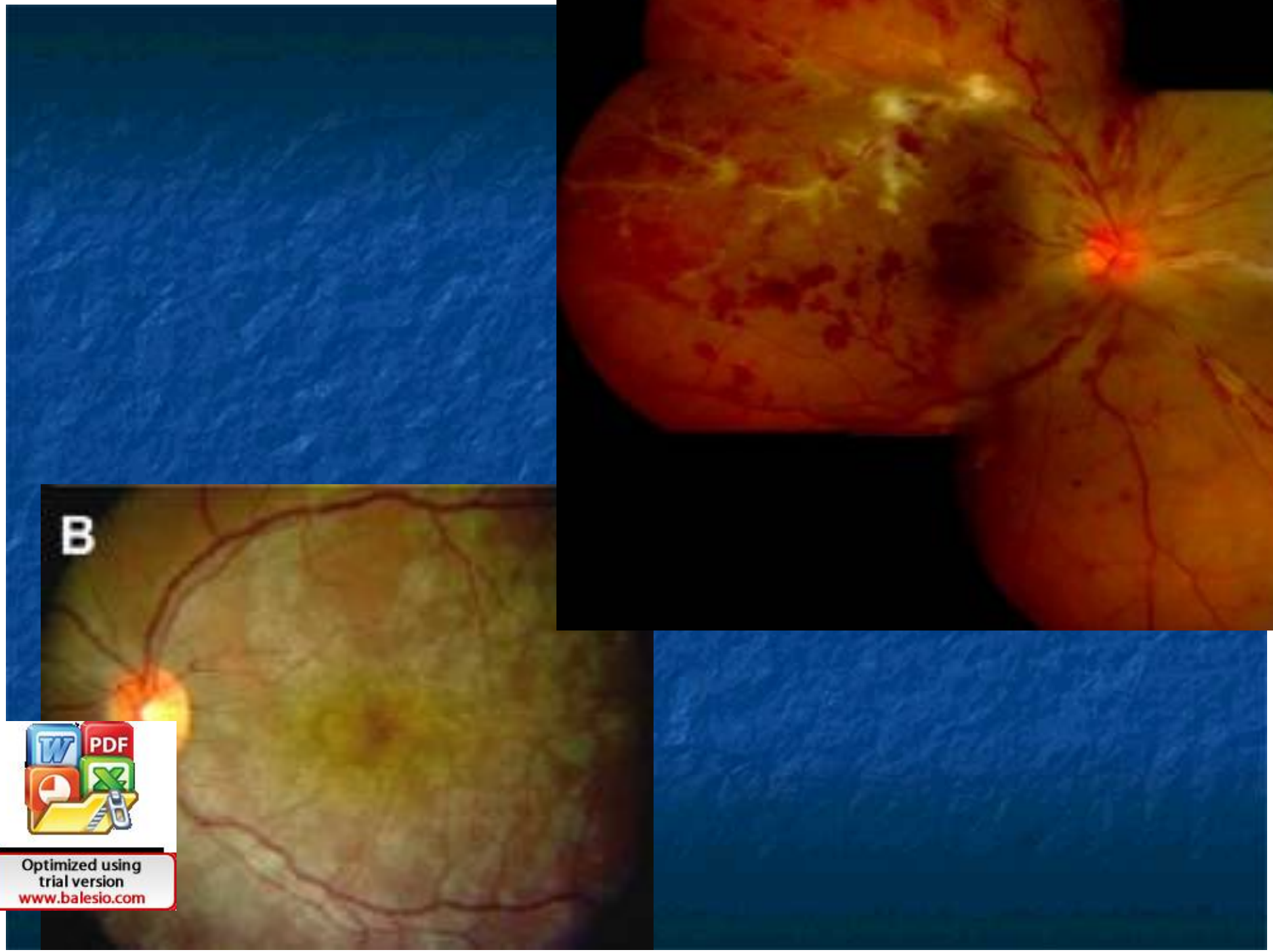

Optimized using
trial version
www.balesio.com

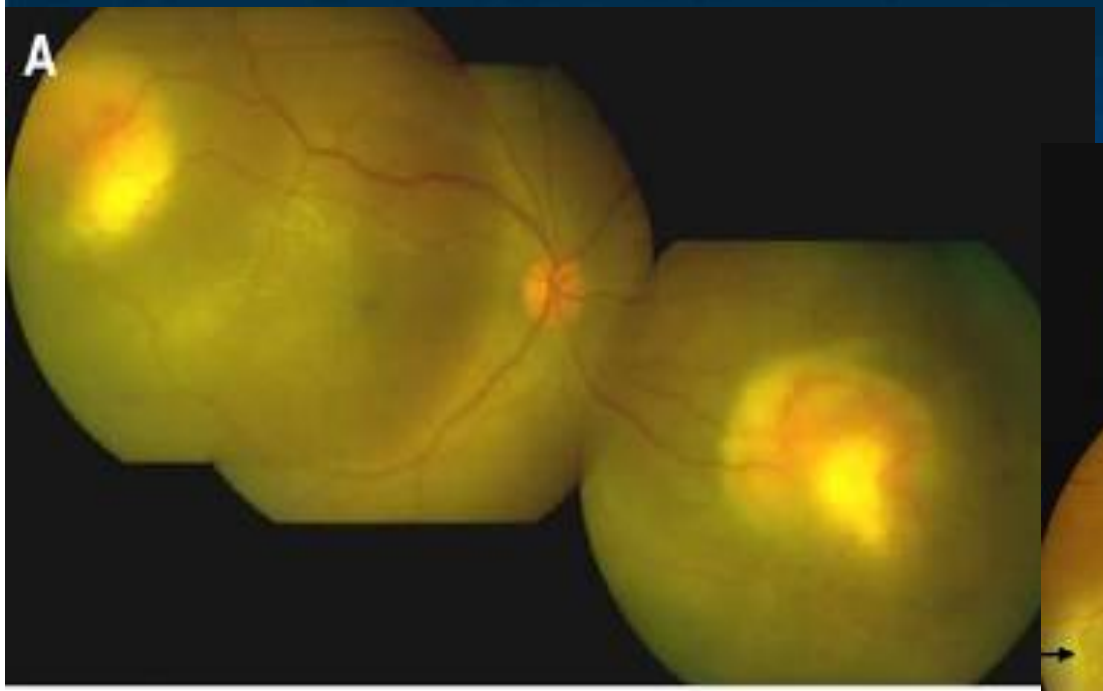

Optimized using
trial version
www.balesio.com

Diagnóstico

- Clínica
- Rx Tx, Mantoux
- Dx de certeza
- Dx de TB latente
- Otros:
  - PCR: muchos falsos +
  - Quantiferón: útil pero caro
  - IGRA (interferón gamma release assays)
  - Serodiagnóstico: muchos falsos +

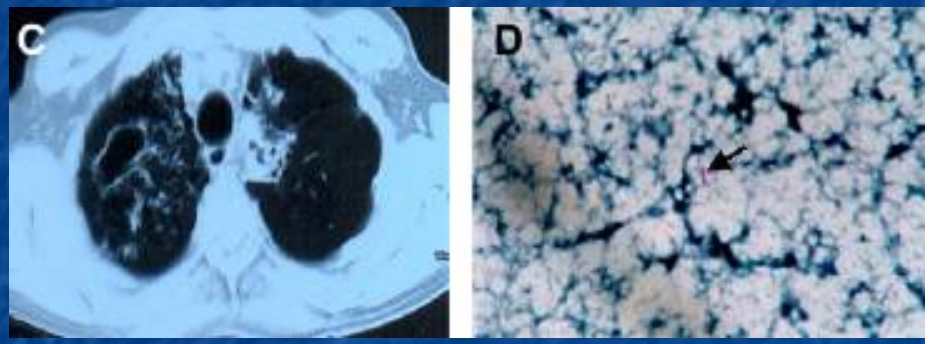

Optimized using
trial version
www.balesio.com

Tratamiento

- TB latente: isoniacida 9 meses, 3cc/día o DOT 2 veces/semana
- Siempre acompañada de GC
- Los antiTB disminuyen en un
  - 90% el riesgo de desarrollar TB activa si la tienes latente
  - 66% el riesgo de recurrencia de uveítis Mantoux +

Optimized using
trial version
www.balesio.com

- Hasta 17% de resistencia a isoniacida
- Con piridoxina para evitar la hepato y neurotoxicidad en DM, alcoholismo, VIH, enf. Hepática y malnutrición

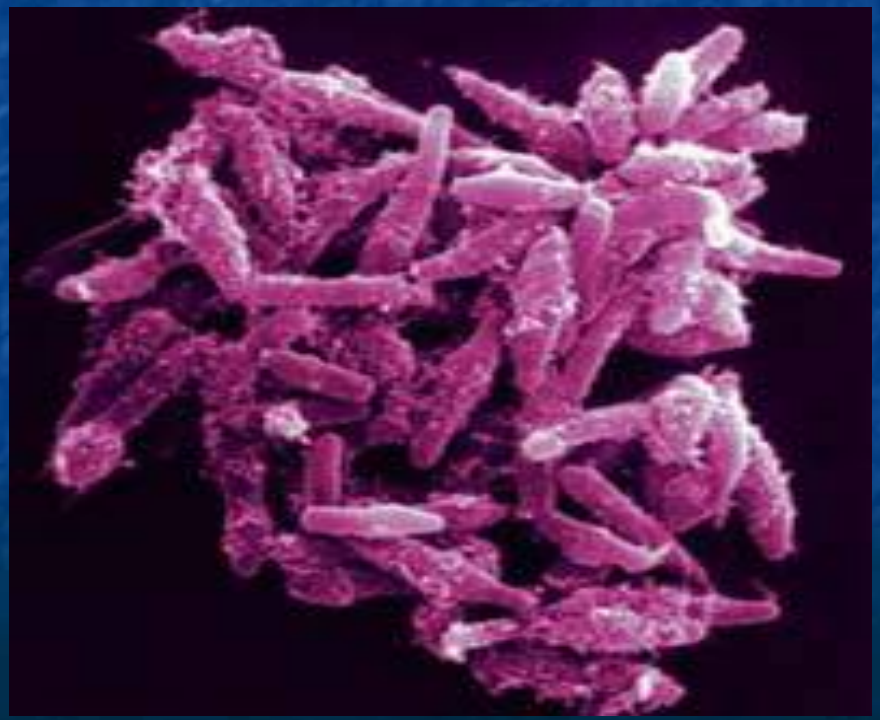

Optimized using
trial version
www.balesio.com

Caso Clínico 1

- Mujer 28 años
- Disminución AV OD, subaguda, indolora
- Vive con gato. Tatuaje
- Exploración
  - AV= 0,2
  - Tyndall vítreo AO, >OD
  - Funduscopia

Optimized using
trial version
www.balesio.com

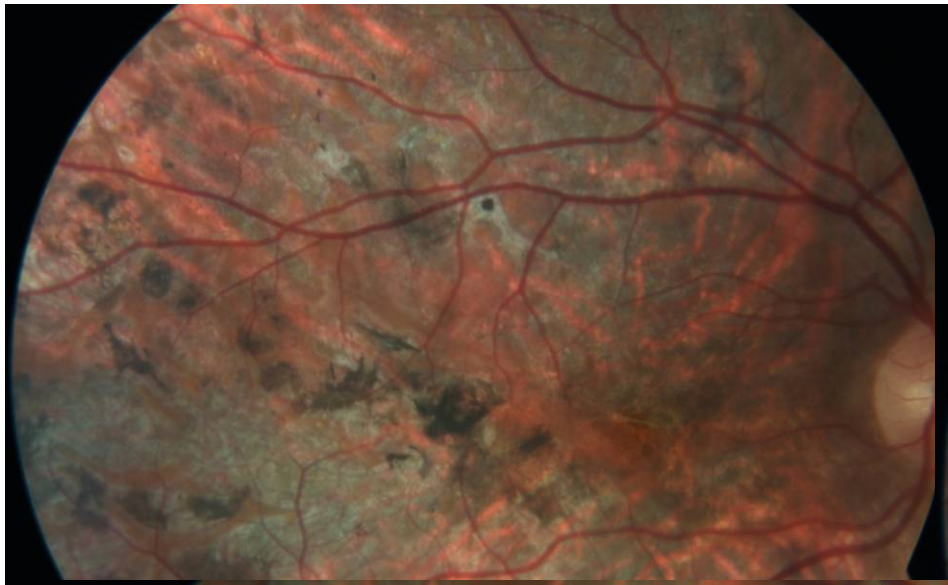

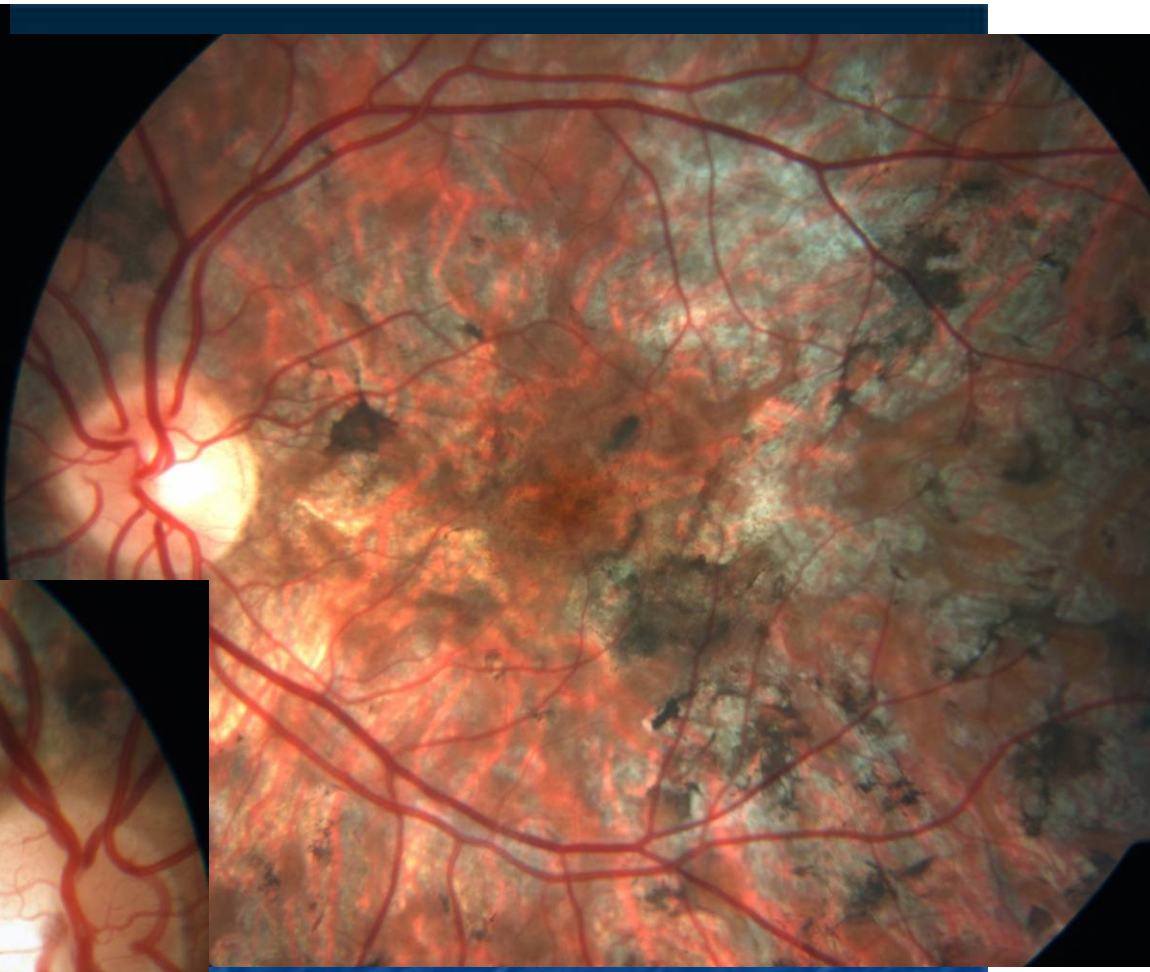

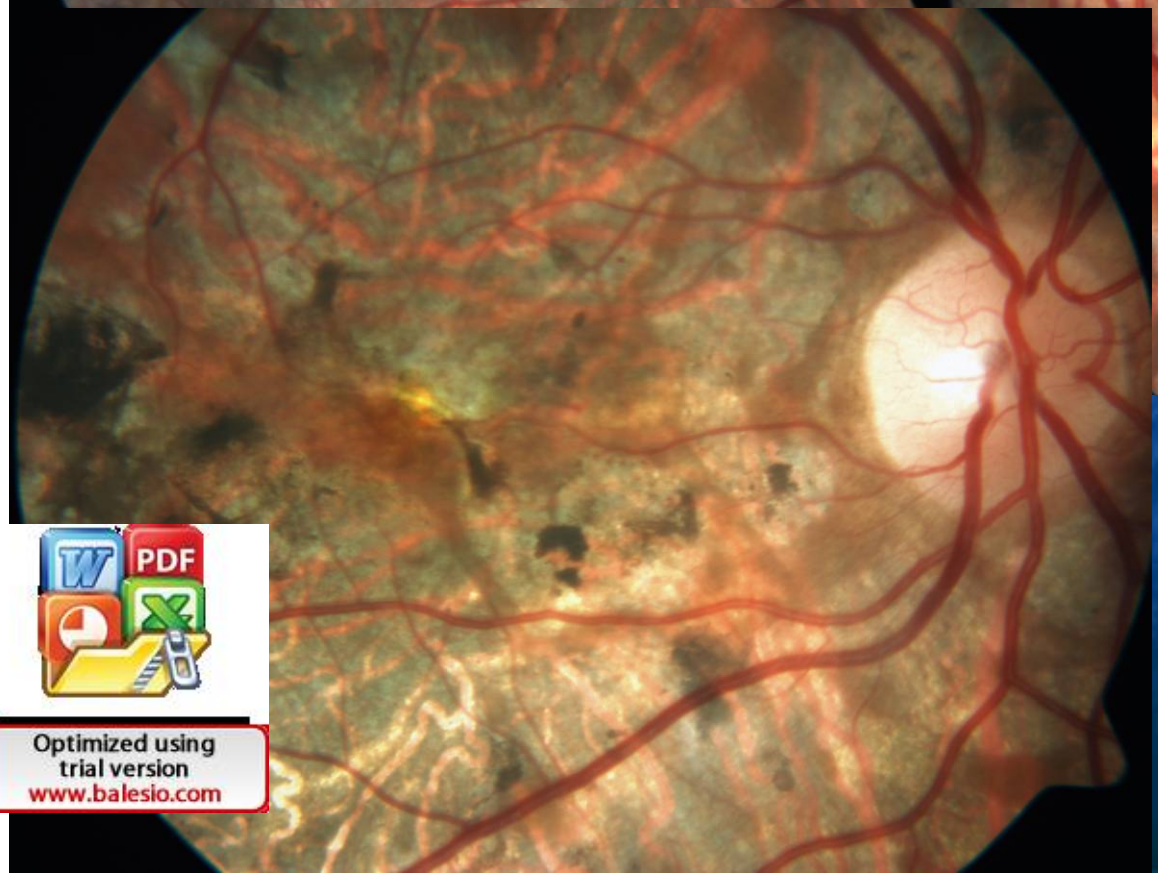

Optimized using
trial version
www.balesio.com

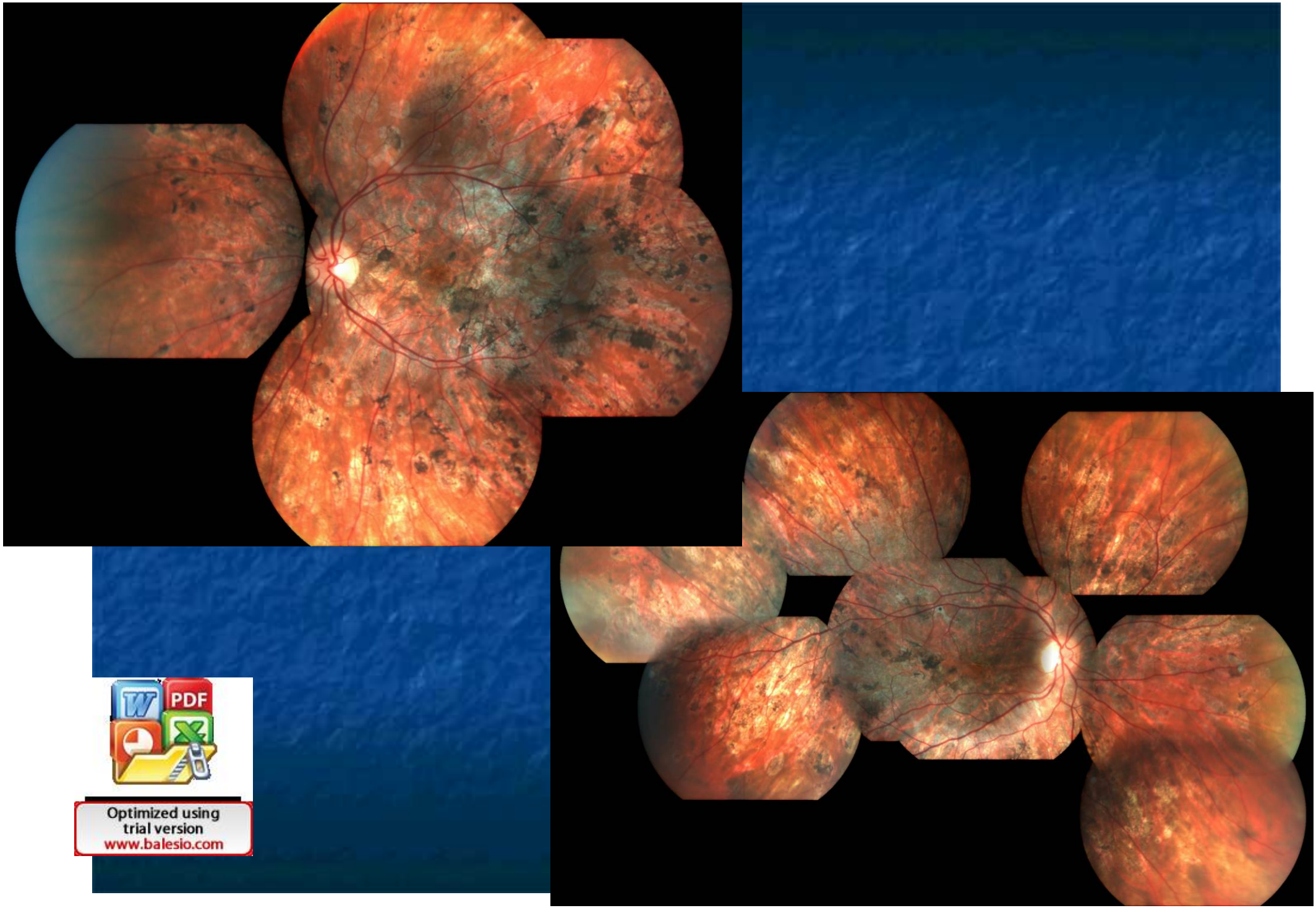

Optimized using
trial version
www.balesio.com

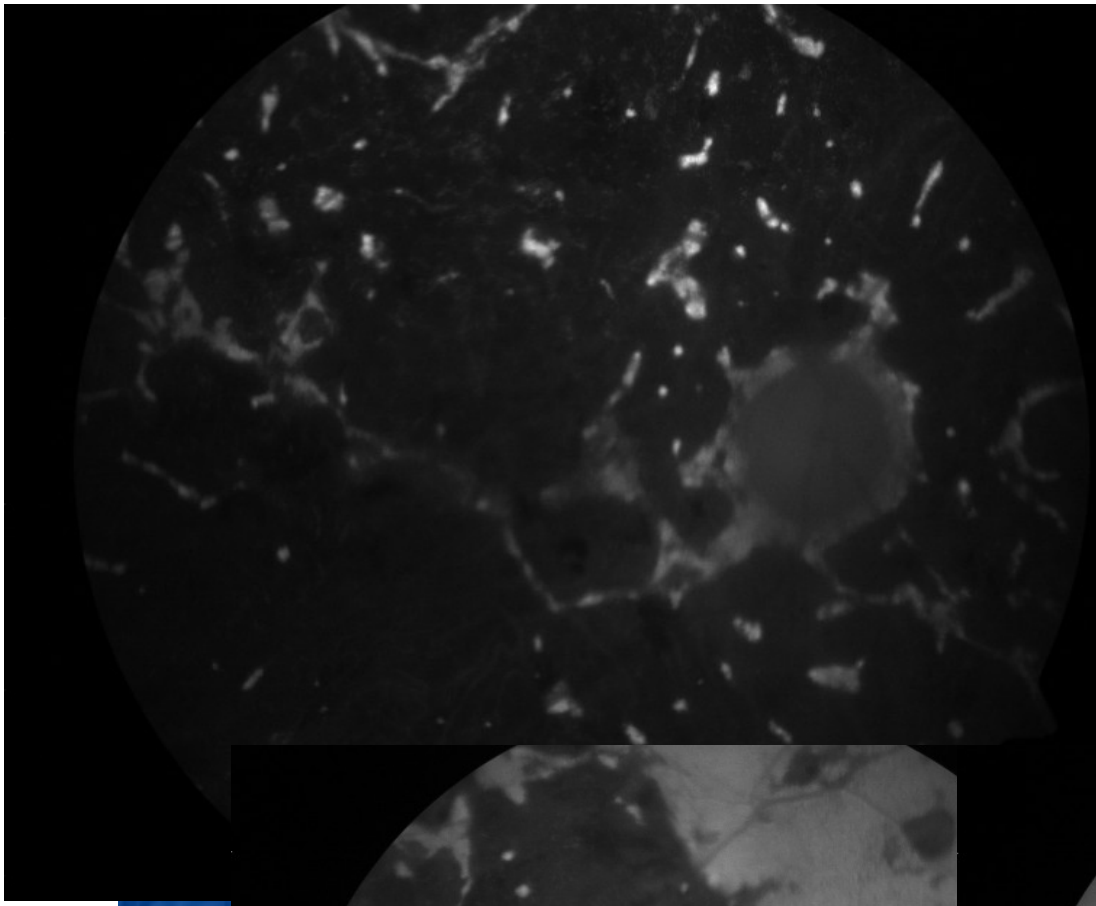

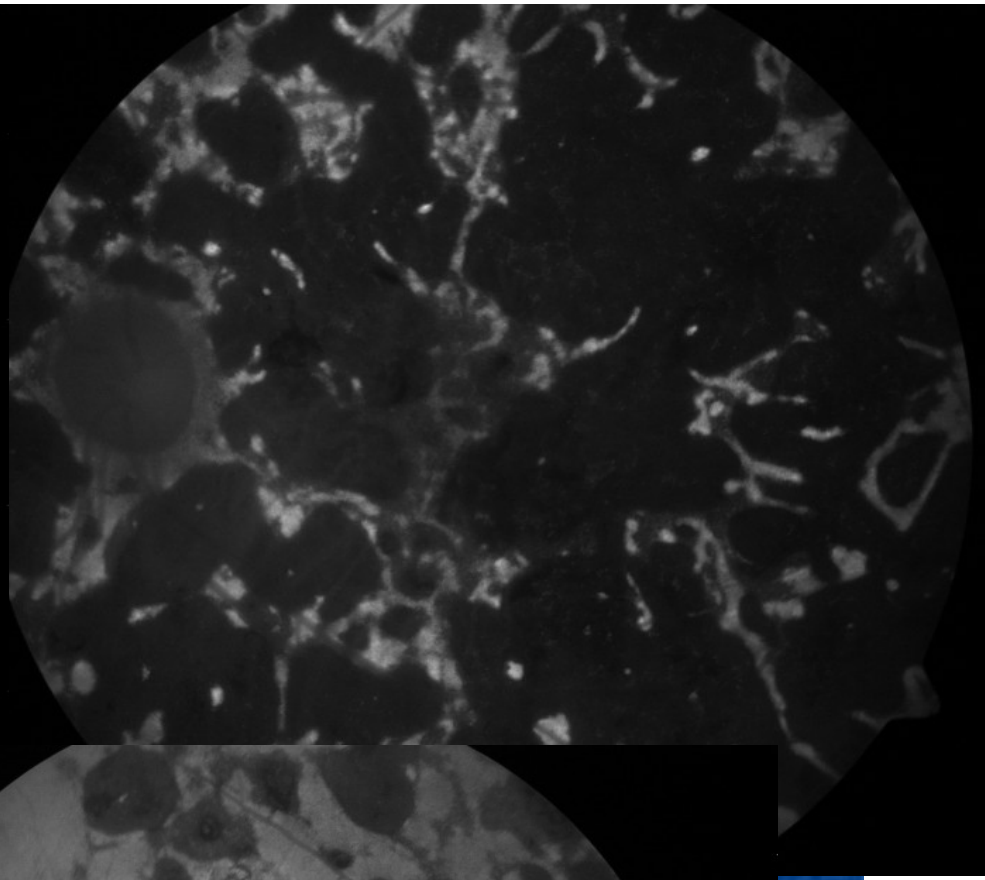

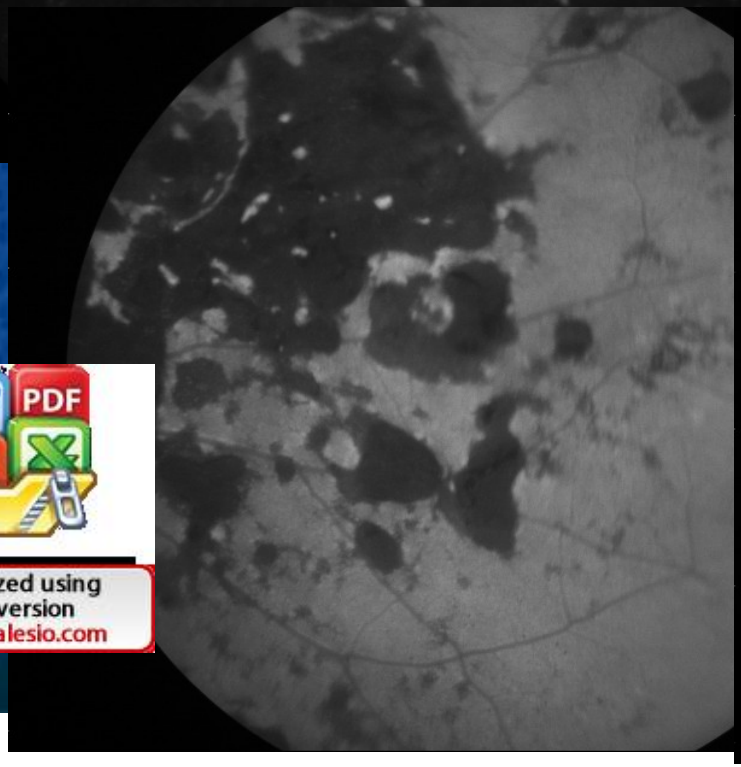

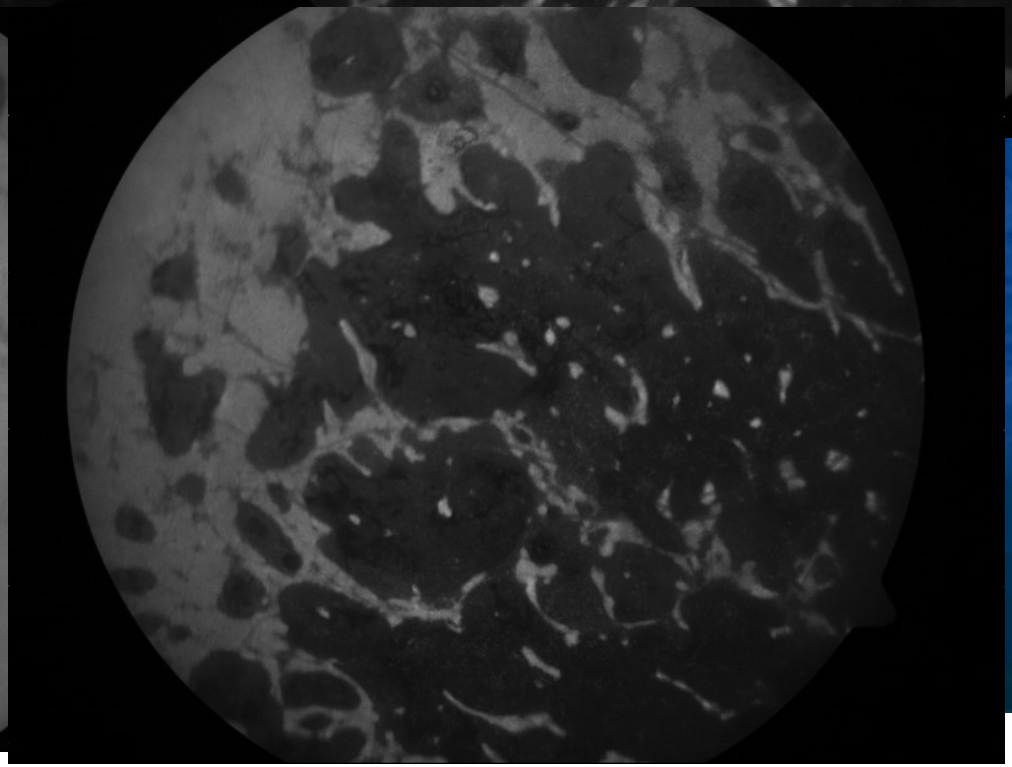

Optimized using
trial version
www.balesio.com

- VIH, Rx tx, ECA, Lúes, Borrelia, ANA, VHC
- Mantoux 22mm
- Tto
  - Trigon transeptal
  - Isoniacida 3cc/día, 9 meses
- A las 7 semanas: AV 1
- CV: escotomas arciformes sup e inf con otro
  racentral inf en OD; en OI paracecal inferior
  semanas sin recurrencias

Optimized using
trial version
www.balesio.com

Pérdidas de fijación: 0/0
Errores falsos positivos: 9 %
Errores falsos negativos: 9 %
Duración de la prueba: 06:06

Foveal: APAGADO

Estrategia: SITA-Standard RX: DS DC X Edad: 28

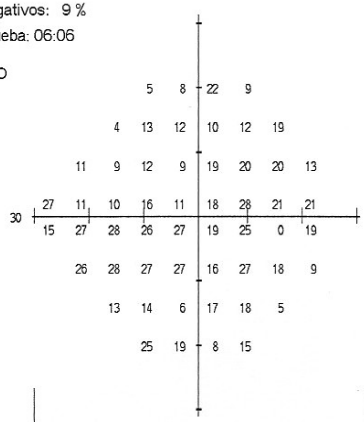

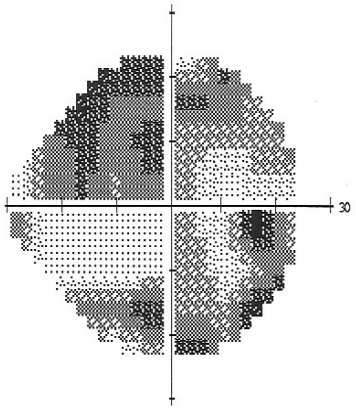

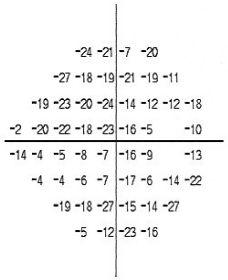

Desviación total

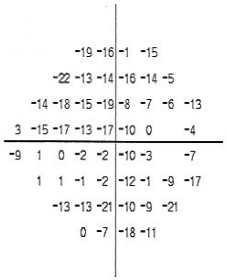

Desviación del modelo

PHG
Fuera de límites normales

VFI 59%

DM -14.75 dB P < 0.5%
DSM 7.48 dB P < 0.5%

:: < 5%
< 2%
< 1%
< 0.5%

COMPLEJO HOSPITAL PONTEVEDRA
C/LOUREIRO CRESPO, S/N
TEL. 986 80 00 00 - EXT.287451
HTTP://WWW.SERGAS.ES

Optimized using
trial version
www.balesio.com

© 2007 Carl Zeiss Meditec
HFA II 745-1392-A10.1/4.2

Pérdidas de fijación: 0/0
Errores falsos positivos: 15 % xx
Errores falsos negativos: 12 %
Duración de la prueba: 07:07

Foveal: APAGADO

Estrategia: SITA-Standard RX: DS DC X Edad: 28

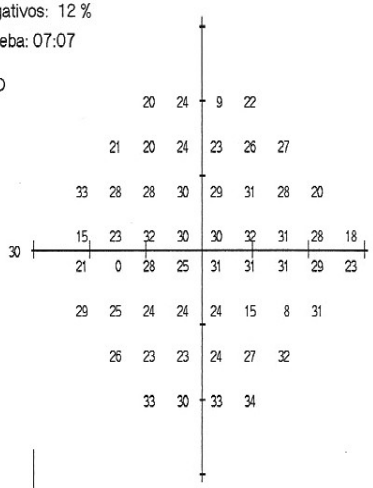

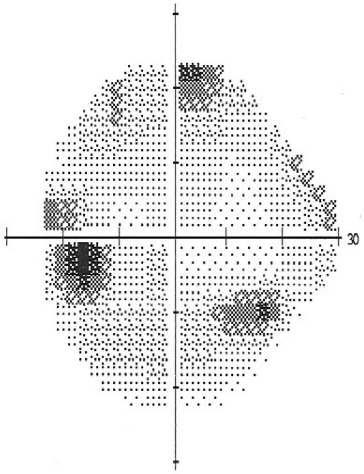



Desviación total

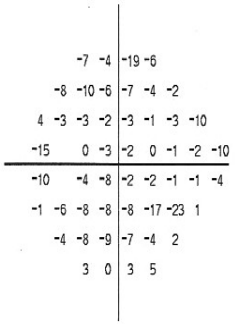

Desviación del modelo

*** Excesiva cant. falsos positivos altos

PHG
Fuera de límites normales

VFI 87%

DM -5.83 dB P < 0.5%
DSM 5.95 dB P < 0.5%

:: < 5%
< 2%
< 1%
< 0.5%

COMPLEJO HOSPITAL PONTEVEDRA
C/LOUREIRO CRESPO, S/N
TEL. 986 80 00 00 - EXT.287451
HTTP://WWW.SERGAS.ES

Caso Clínico 2

- Varón, 52 años, FEA Medicina Interna
- HTA, FA, HiperTGL
- 2007: dx de coroiditis sine philiatio
- RX, ECA, VIH, Lúes… normal
- Mantoux 17 mm
- Recidivas hasta tto antiTB
- Tto: 2 meses IRP, 4 meses IR

Optimized using
trial version
www.balesio.com

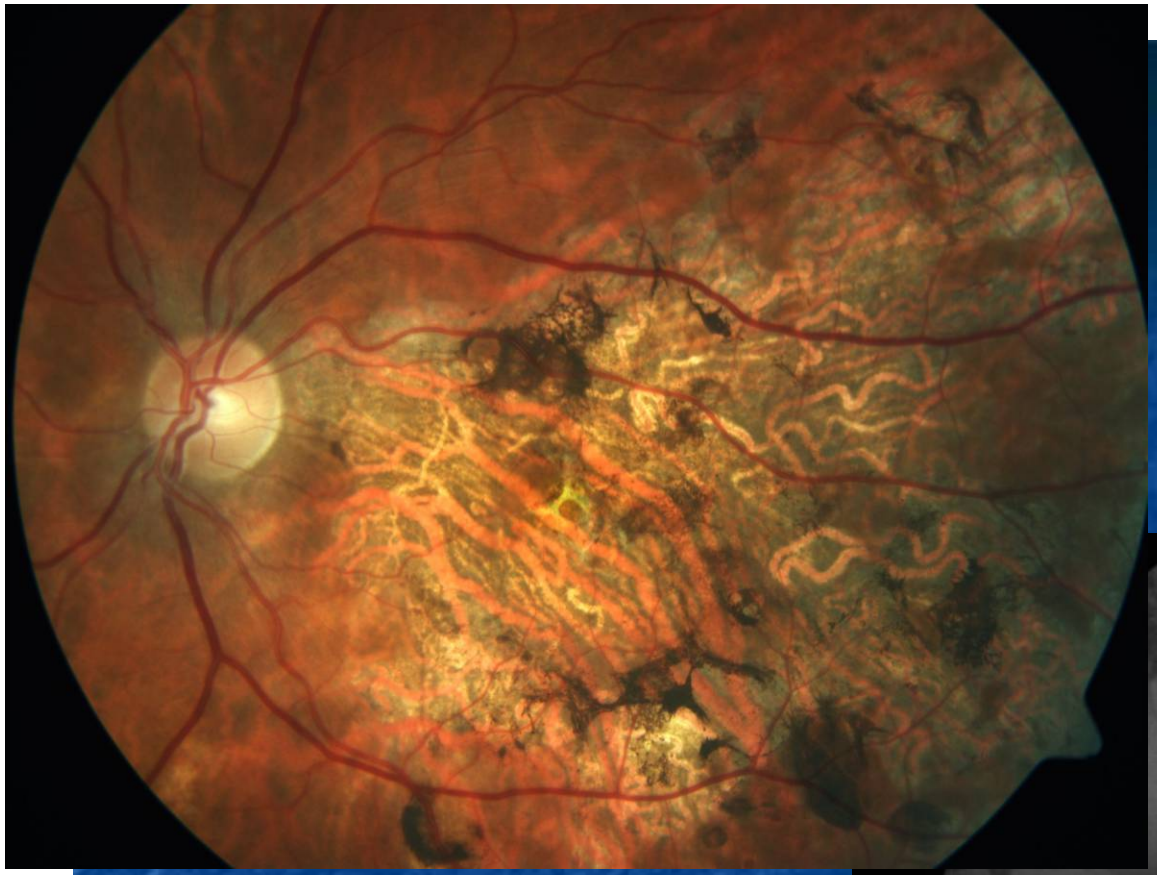

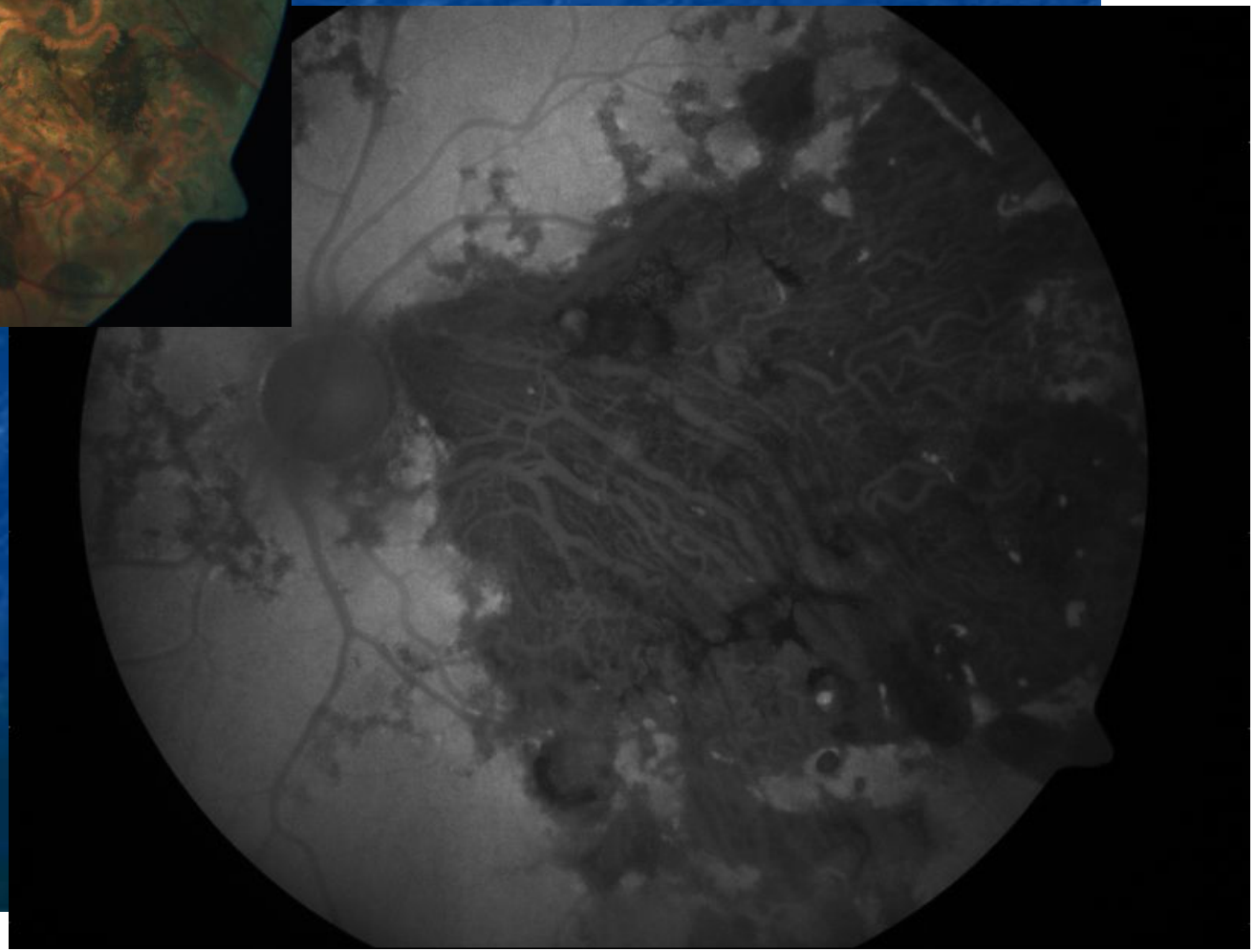

Optimized using
trial version
www.balesio.com

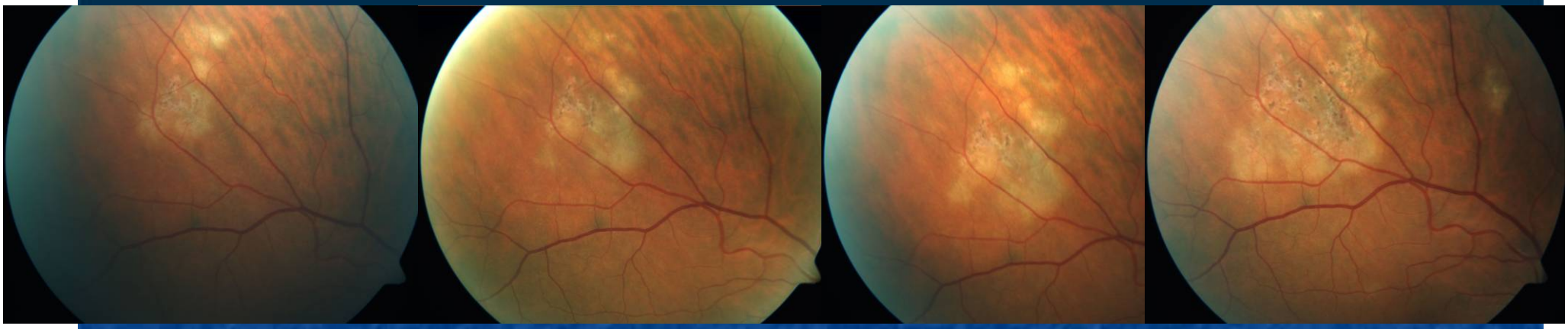

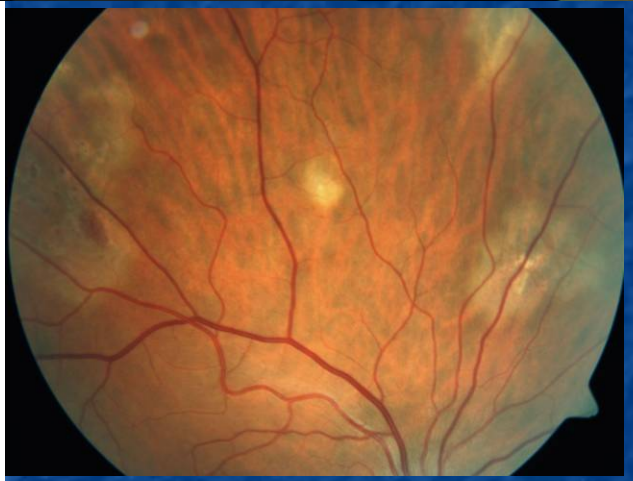

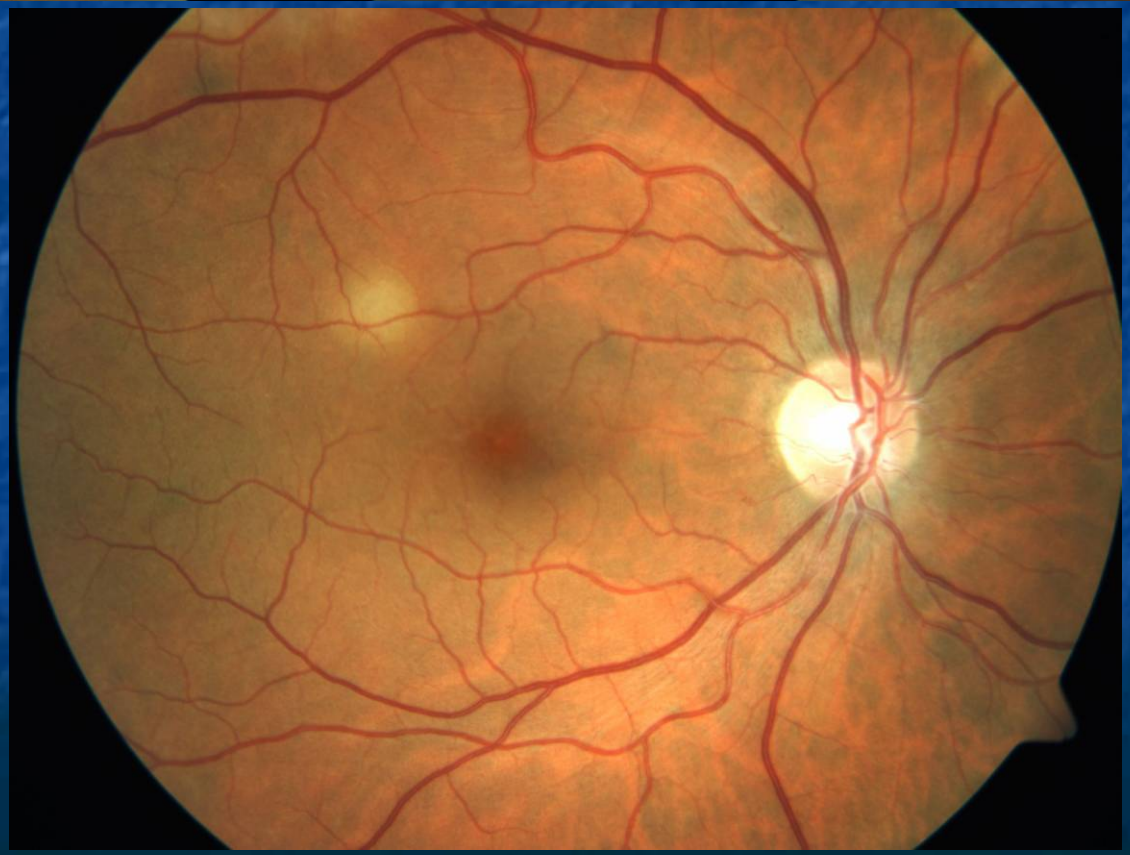

Optimized using
trial version
www.balesio.com

Optimized using
trial version
www.balesio.com

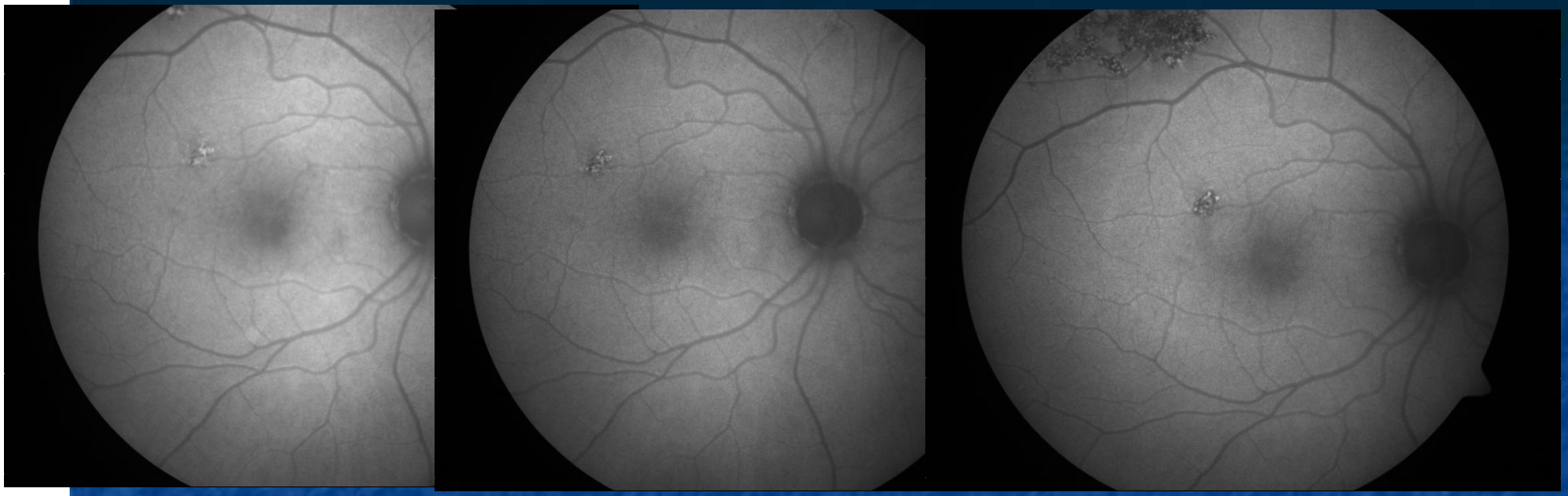

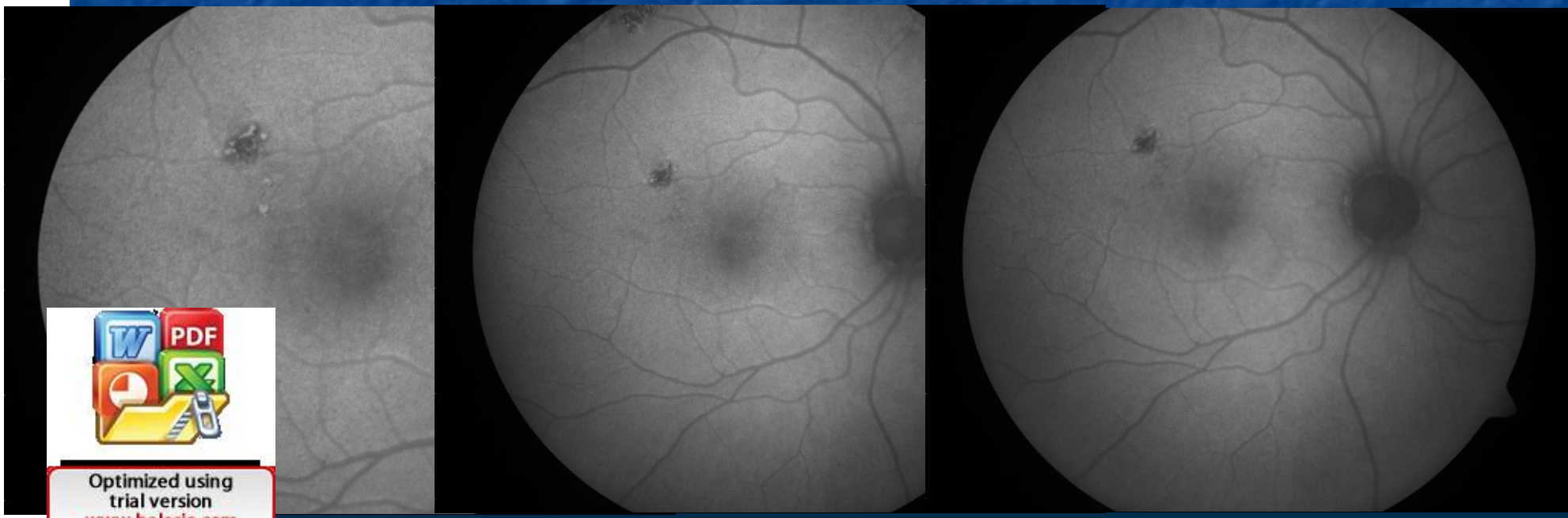

Optimized using
trial version
www.balesio.com

Autofluorescencia

- Distribución de lipofuscina en el EPR
- 535-585 nm de excitación; 615-715 nm de filtro barrera
- No invasiva
- Hiper: acúmulo de lipofuscina

Optimized using
trial version
www.balesio.com

AF en TB

- Coroiditis multifocal: Puntos de <125 micras hipoautofluorescentes
- Serpiginosa y EPPMA
  - se mantiene hiperautofluo mientras está activa la lesión y hasta 4-5 días después => buen indicador de actividad
  - Predice el área de atrofia final del EPR
- Muestra más alteraciones que AFG ó ICG
- ejor relación topográfica con la mácula
- escarta neovascularización

Optimized using
trial version
www.balesio.com

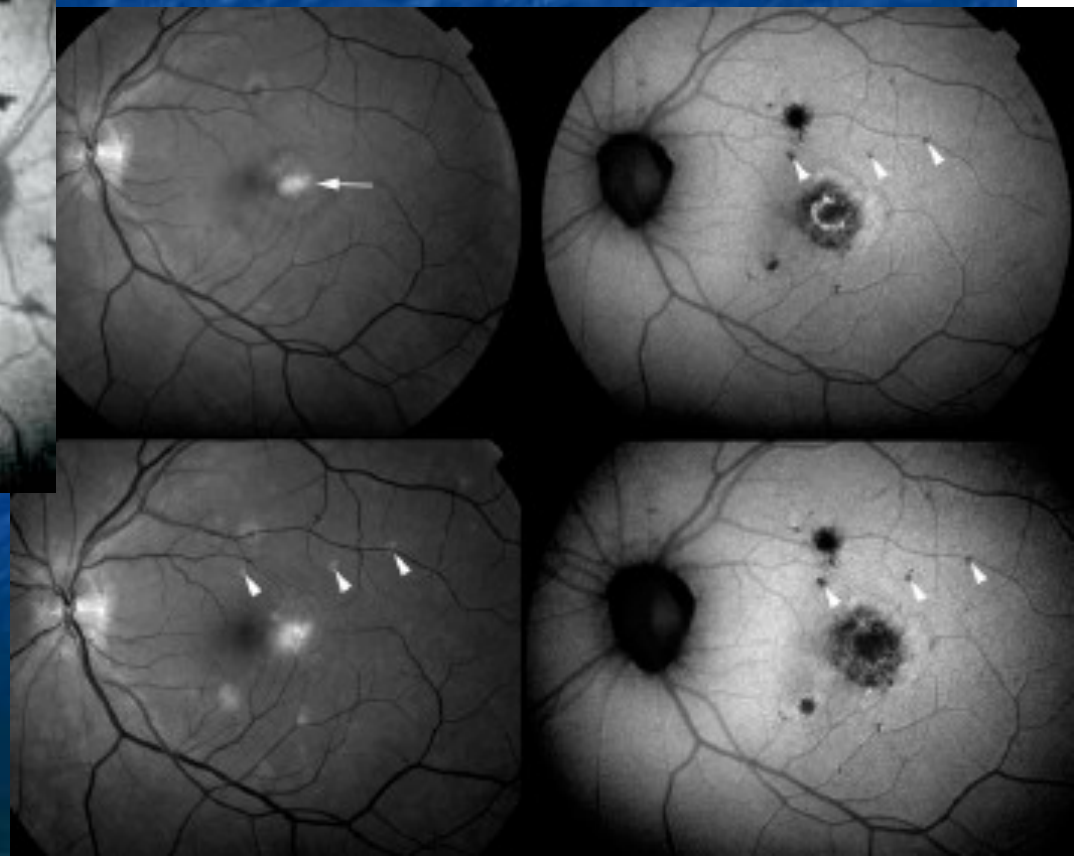

Optimized using
trial version
www.balesio.com

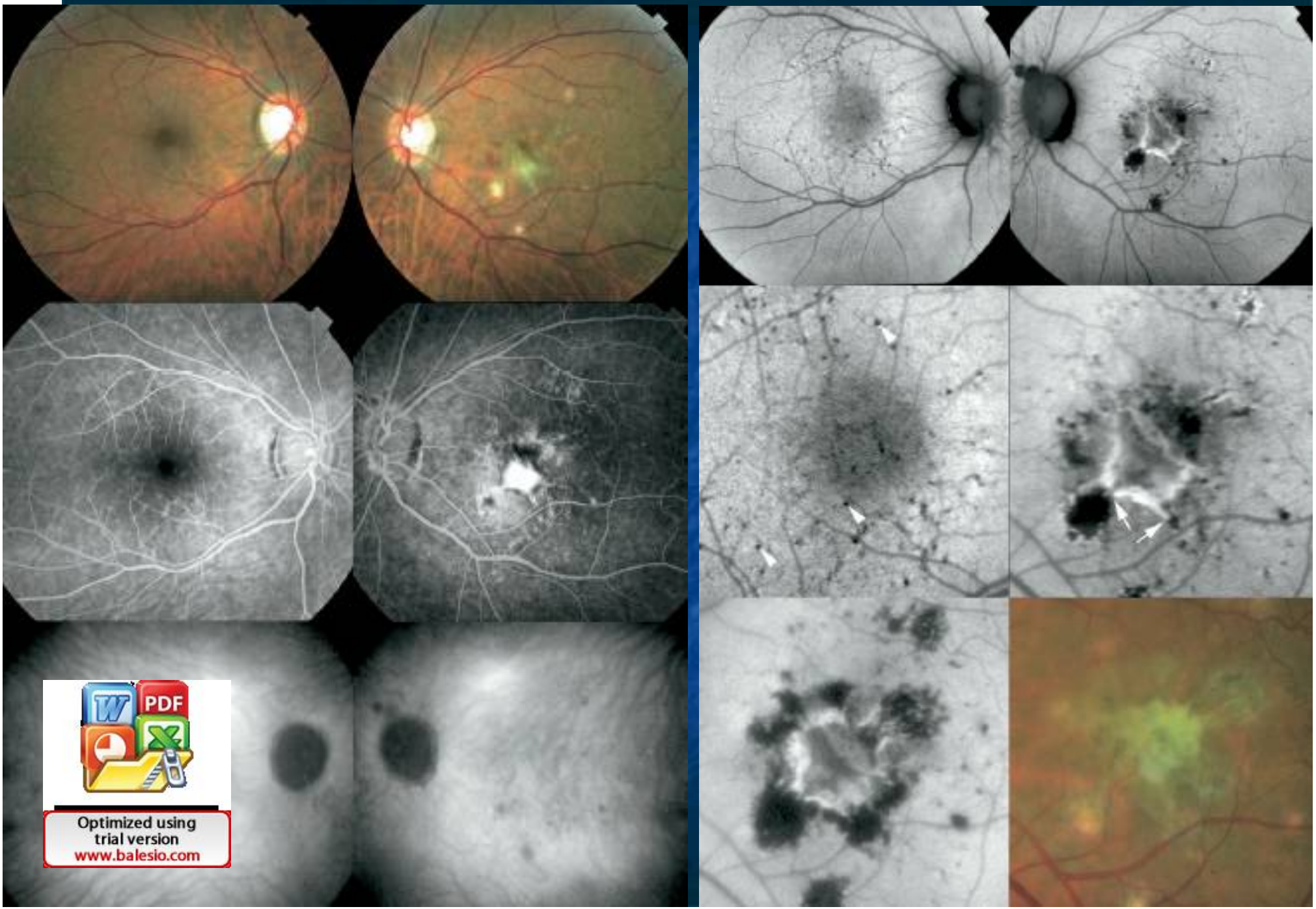

Optimized using
trial version
www.balesio.com

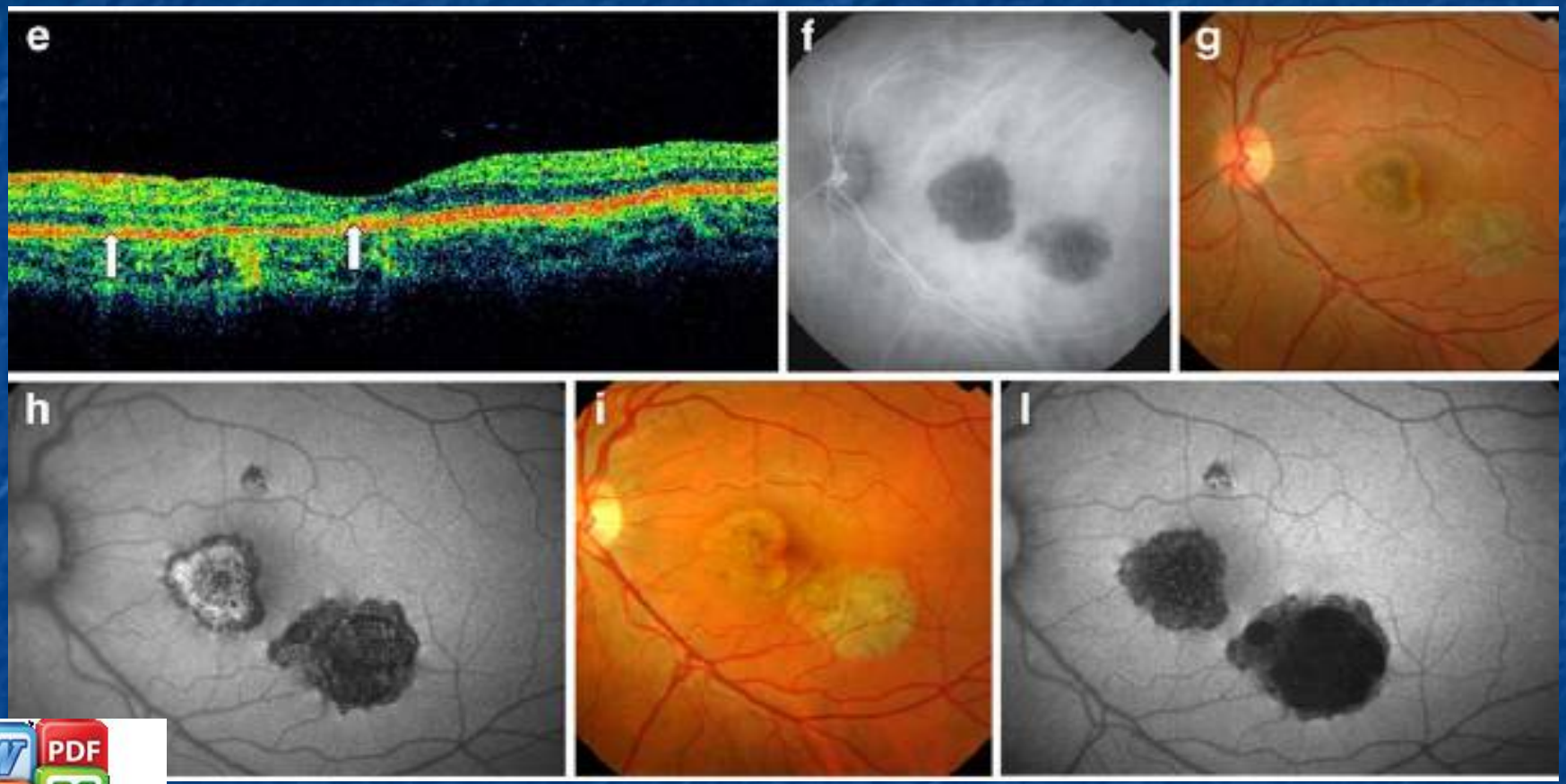

Optimized using
trial version
www.balesio.com

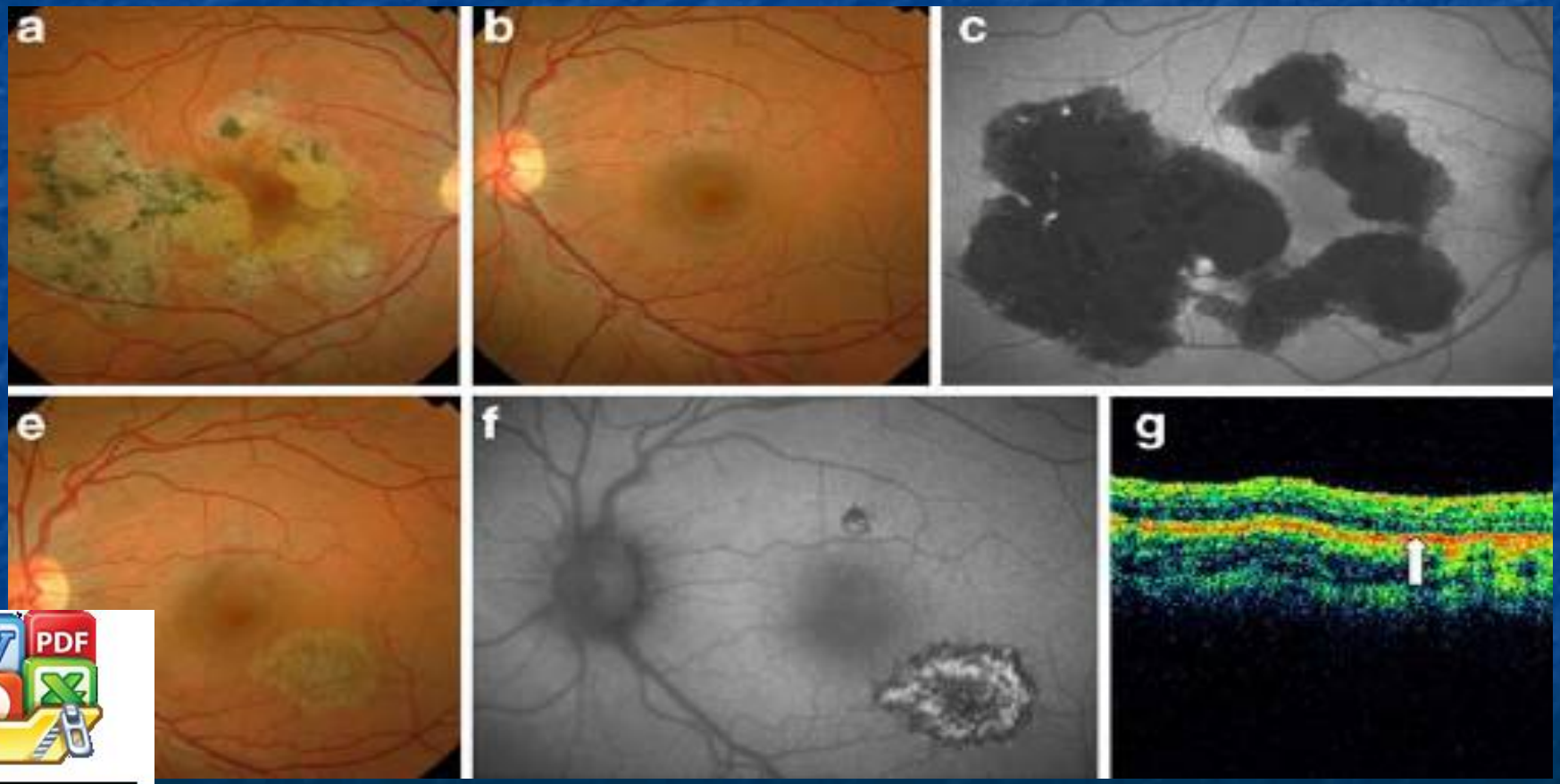

Optimized using
trial version
www.balesio.com

Conclusiones

- Concepto de TB latente
- Eficacia de tto de TB latente
- Autofluorescencia
  - Anticiparse a la actividad
  - Seguimiento y ajuste de tto
  - Pronóstico

Optimized using
trial version
www.balesio.com

Bibliografía

- Bansal R, Gupta A, Gupta V, Dogra MR, Bambery P, Arora SK. Role of anti-tubercular therapy in uveitis with latent/manifest tuberculosis. AM J Ophthalmol. 2008 Nov; 146(5):772-9.
- Tabbara KF. Tuberculosis. Curr Opin Ophthalmol. 2007 Nov;18(6): 493-501.
- Gupta V, Gupta A, Rao NA. Intraocular tuberculosis--an update. Surv Ophthalmol. 2007 Nov-Dec;52(6):561-87.
- MMWR Recomm Rep. 2000 Jun 9;49(RR-6):1-51.Targeted tuberculin testing and treatment of latent tuberculosis infection. American Thoracic Society.
- Cardillo F, Grosso A, Savini E. Fundus autofluorescence in serpiginous choroiditis. Graefes Arch Clin Exp Ophthalmol (2009) 247:179–185
- Haen Sp, Spaide RF. Fundus autofluorescence in multifocal choroiditis and panuveitis.Am J Ophthalmol. 2008 May;145(5):847-53
- Alvarez GG, Roth VR, Hodge W. Ocular tuberculosis: diagnostic and treatment challenges. Int J Infect Dis. 2009 Jul;13(4):432-5
- Cohen D, Rambeloarisoa J, Florea L, Leye YM. Diagnostic and therapeutic challenges. Retina. 2009 Jan; 29(1):117-20

Optimized using
trial version
www.balesio.com